

**CLINICAL SKILL HANDOUT  
FORENSIC MEDICINE AND MEDICOLEGAL**



**Clinical Skill Lab Forensic Medicine-Medicolegal  
Medical Faculty of Hasanuddin University  
Makassar  
2015**

## TABLE OF CONTENT

Handout Cover	
Table of Content .....	1
Preface .....	2
Wound Examination (theoretical background) .....	3
Learning Objective .....	6
Learning Strategies .....	7
Body Sketch .....	8
Wound Examination Procedure .....	11
Evaluation .....	15
Reference .....	

## PREFACE

After graduation, any doctor may encounter to examine a person who has been wounded, particularly if it involve casualty. The condition of the wound may be trivial or serious and the injured person may be alive or dead. Therefore, it is utmost important for a doctor to have the ability to conduct identification and description of wounds, which may have serious medico-legal implications at a later stage. Because of that, it is essential that different types of wounds should be scrutinized correctly and identified as well as described, with a full description being made in notes and photographs taken at the time of the examination.

This Clinical Skill Handout is design for medical student in Forensic Medicine and Medico legal. The major objective of this manual is that the student can master the skill of assessing and documenting different types of wounds and later reporting those finding in a Visum et Repertum report.

We would like to appreciate to all contributors who have helped in compiling this Clinical Skill Manual.

Makassar, 1 October 2010  
Coordinator of Clinical Skill Lab  
Forensic Medicine and Medicolegal

## **WOUND EXAMINATION IN FORENSIC MEDICINE AND MEDICOLEGAL**

### **CLASSIFICATION OF WOUNDS**

The identification and description of wounds may have serious medico-legal implications at a later stage, and often after some considerable time has passed since the wounding. It is therefore essential that different types of wounds can be correctly identified and described, with a full description being made in notes taken at the time of, or shortly after the examination ('contemporaneous notes').

A wound is the term given to tissue damage caused by mechanical force (also called injury or trauma). This includes wounds caused by stabbing, blunt trauma (punching, kicking, beating etc), strangling, biting, shooting, falling from a height, being hit by a vehicle, and blast trauma from explosives.

**Descriptions of wounds** should include:

- the nature of the wound, i.e. whether it is a bruise, abrasion or laceration etc
- the wound dimensions, e.g. length, width, depth etc. It is helpful to take a photograph of the wound with an indication of dimension (e.g. a tape measure placed next to the wound), and for measurements to be taken of the wound as it appears first, and then with wound edges drawn together (if it is a laceration etc).
- the position of the wound in relation to fixed anatomical landmarks, e.g. distance from the midline, below the clavicle etc.
- the height of the wound from the heel (i.e. ground level) - this is particularly important in cases where pedestrians have been struck by motor vehicles

The main types of wounds that often found in our daily life, including

- abrasions
- bruises/ contusions
- lacerations

- incised wounds
- stab wounds
- fractures
- bite marks
- defense injuries

### **Abrasions (Scrapes)**

An abrasion is denuded skin caused by friction. A wound may be either deep or superficial depending on the force and the coarseness of the surface which caused the abrasion. A person who slides across pavement might have a deeper and rougher wound than a person who slides across a rug. Occasionally, the direction of the force can be determined. If one end of a wound has margins with raised skin, for example, the force originated from the opposite side.

### **Contusions (Bruises)**

Contusions are discolorations of the skin caused by bleeding into the tissues from ruptured blood vessels. In general, the older a person, the easier the vessels will rupture. There is no way, however, to determine exactly how much force is needed to produce a contusion. The age of a contusion is difficult to determine because of the great variability of a body's reaction to trauma. People with blood disorders and liver disease may develop more severe contusions than healthy individuals. As healing occurs, a contusion changes color from blue or red, to red-blue, to green, to brown, and finally yellow. These color changes, however, may appear out of order and may overlap. There is no way to know how long each color stage will last. Occasionally a recent contusion will have a brown tinge.

### **Lacerations (Tears)**

Tears of the skin from blunt trauma are called lacerations. Many tears are associated with both contusions and abrasions. For example, a blow to the head with a hammer may cause tearing of the scalp with adjacent abrasions. If blood escapes into the surrounding tissues, the skin can also be bruised. A laceration must be distinguished from a cutting

injury. A laceration usually has bridges of tissue connecting one side of the wound to the other. Cutting and incised wounds have no tissue bridges because a sharp object cuts the wound cleanly from the top to the bottom of the wound.

Deaths due to blunt trauma may have some or none of the above external signs of trauma. This is particularly true of fatal blows to the abdomen.

### **Blunt trauma to the head**

Blunt trauma to the scalp and face can produce contusions, lacerations, and abrasions. However, there may be no external signs of trauma to the head if a person has a full head of hair. Obvious external injuries are not necessary for a death to be caused by head trauma. Occasionally, the weapon leaves a characteristic identifying pattern on the scalp. Unfortunately, this is the exception rather than the rule.

**Battle's sign** — a bluish discoloration of the skin behind the ear that occurs from blood leaking under the scalp after a skull fracture.

**Spectacle hemorrhage (raccoon's eyes)** — a discoloration of the tissues around the eyes usually due to a fracture of the skull. The hemorrhages may involve one or both eyes and may be mistakenly interpreted that the decedent had been struck about the face and eyes. When a person receives a significant blow to the head there will be bleeding under the scalp even if there are no external injuries. Depending on the amount of force there may be skull fractures. There are many different types of skull fractures; however, the specific type is not as important as recognizing a pattern such as a circular fracture caused by a hammer.

## **LEARNING OBJECTIVE**

### **General Objective**

After conducting the skills in this manual, students are expected to be able to master the skill of assessing different types of wounds.

### **Specific Objective**

After finishing the skills training in this manual, students are expected to be able to conduct :

1. Proper observation and identification skill
2. Correct assessment of different types of wound
3. Correct description of different types of wound found on patient body
4. Correct identification of the object / weapon that cause the injury using the characteristic of the wound.

## **LEARNING STRATEGIES**

### **Instruments and Tools :**

- Manual book of CSL for wound
- Handscoen / Surgical gloves
- Standart measurement / Ruler
- Surgical Tapes
- Patient status (body sketch), ballpoint
- Audio-visual / Digital Camera

### **Learning Method :**

1. Demonstration due to manual book
2. Discusssion
3. Active participation (simulation)
4. Evaluation using check list

# Body Sketch

**BODY SKETCH** (described in item 22 and/or 31, 53)

**Mark on charts**

- Damaged
- Burnt
- Decomposed
- Skeletonized
- Missing
- Loose
- Scars/Piercing
- Skin marks
- Tattoo marks
- Malformations
- Amputations

Please draw

Please draw

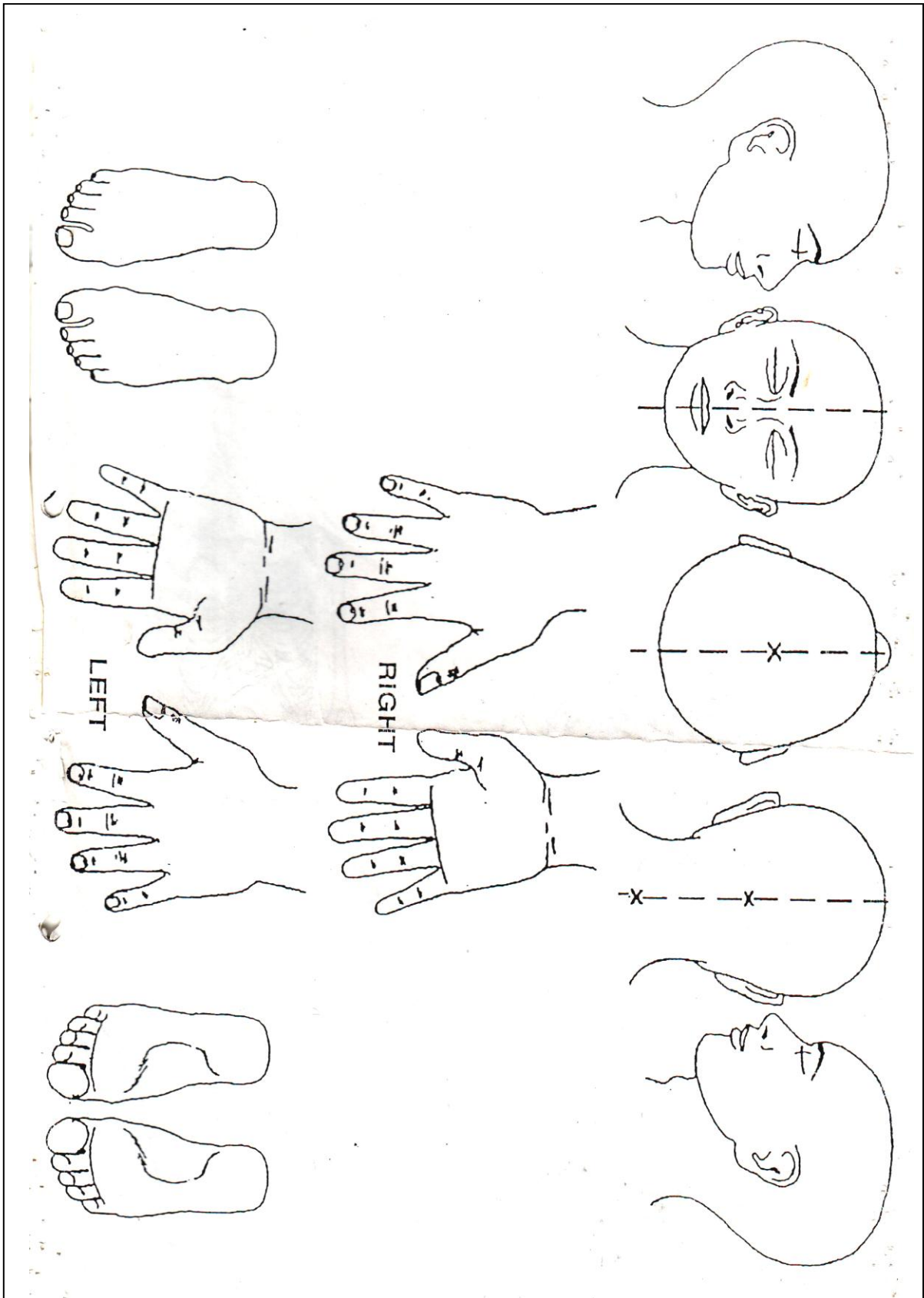
Please draw

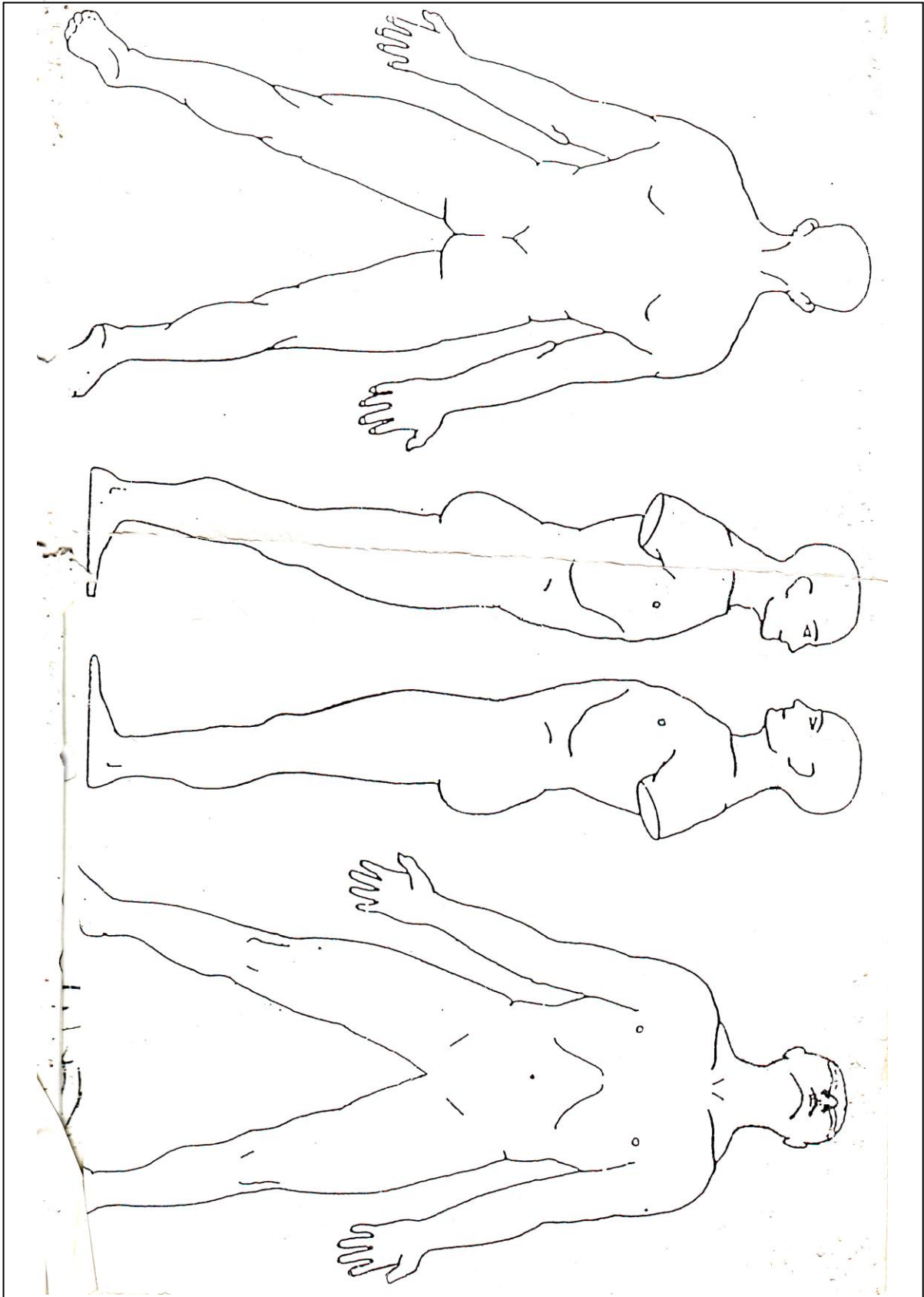
Please draw

Please draw

RIGHT

LEFT





## Wound Examination Procedure

No	Activity
1	<p>Check all the administration and the equipment required:</p> <ol style="list-style-type: none"> <li>a. External examination request letter (SPV)</li> <li>b. Body label (big and small)</li> <li>c. Material label (big and small)</li> <li>d. Pen</li> <li>e. Digital camera</li> <li>f. Handscoen (gloves)</li> <li>g. Measurement standart</li> </ol>
2	<p>Write down the required information from the external examination request letter (SPV) to the body label and to the body chart:</p> <ol style="list-style-type: none"> <li>a. Police request number</li> <li>b. Victim's name / age</li> <li>c. Case register number</li> <li>d. Examiner name</li> <li>e. Examiner ID number</li> <li>f. Date of the examination</li> <li>g. Time of the examination</li> </ol>
3	<p>Wear the surgical gloves (handscoen)</p>
4	<p>Describe the wound and write it down on the body chart</p> <ol style="list-style-type: none"> <li>I. Number of wound</li> <li>II. Type of wound</li> <li>III. Location (anatomical region)</li> <li>IV. Wound measurement (length and width)</li> <li>V. Location (absis and ordinat)</li> <li>VI. Wound characteristic               <ul style="list-style-type: none"> <li>• Wound border : shape of wound; wound border – even or serrated; end of wound – pointed or blunt</li> <li>• Area inside the wound border : interior slope – even or serrated, type of tissue; tissue bridging; base od wound</li> <li>• Area surrounding the wound border : bruises; blood clot; soot; tattoage; etc.</li> </ul> </li> </ol>

## **Reference**

Dorland's Illustrated Medical Dictionary E-Book 32nd edition. Elsevier Health Science. 2011.

Dolinak D, Evan et al. Forensic Pathology Principle and Practice. Elsevier Academic Press. London. 2005

Skhrum, Micheal J, David A Ramasay et al. Forensic Pathologic of Trauma: Common Problem for the Pathologist. Human Press. New Jersey. 2007