

**MODUL**

# **PROBLEM BASED LEARNING SISTEM INDRA KHUSUS**



- **Modul Gangguan Pendengaran**
- **Modul Gangguan Penciuman**

**Diberikan Pada Mahasiswa Semester V  
Fakultas Kedokteran Unhas**

**Fakultas Kedokteran  
Universitas Hasanuddin  
2016**

**FACULTY OF MEDICINE HASANUDDIN UNIVERSITY**  
**OBJECTIVE STRUCTURED ORAL CASE ANALYSIS**  
**SPECIAL SENSE SYSTEM**  
**OTORHINOLARYNGOLOGY**  
**ACADEMIC YEAR 2016-2017**

**CASE 1**

Women, A, 25 years came to the clinic with chief complaints of hearing loss in right ear since 1 year ago accompanied by a purulent ear charged, smells, sometimes pain and itching and headache. No complaints of vertigo. History of frequent ear probe, a history of the same disease is often recurrent, a family history of atopy denied.

**Physical examinations:**

General conditions: Good, not anemic. Height: 160 cm, Weight: 60 kg.

Vital signs are within normal limit.

Inspection : Auricel normal

Palpation : No edema and no tenderness of tragus and retroauricel

Otoskopi : Right external acoustic meatus and right tympanic membrane hyperemic, subtotal central perforation of right tympanic membrane, mucoid secretions in right tympanic cavity and the external acoustic meatus  
Left acoustic meatus and left tympanic membrane normal

Faringoscopy : Within normal limits

Anterior Rhinoscopy : Nasal cavity, nasal septum and nasal turbinate normal

Laboratory examination: Hb 14 g / dl, leukocytes 12,600 g%, LED 45 / 1 hour

Pure Tone Audiometry Examination :

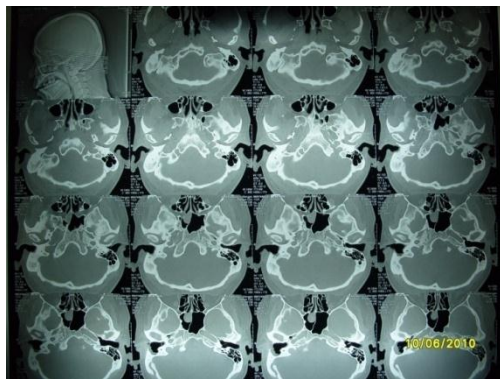
Ear artery: Mild-Severe Hearing Loss Conductive (60 dB)

Ear Sinistra: Normal Hearing (20 dB)

Examination of vestibular function: no canal paresis

Chest X-Ray : Normal

Mastoid CT-Scan :



Diagnosis : Right Chronic Suppurative Otitis Media

Therapy : Antibiotics, antiinflammation, nasal dekonjestan dan mucolitic

**EACH STUDENTS ARE ASSIGNED TO :**

- 1 MAKE A MIND MAP OF CHRONIC SUPURATIVE OTITIS MEDIS:**
- 2 SYMPTOMS AND SIGNS OF HEARING DISTURBANCE**
- 3 EXPLAIN THE ETIOLOGY AND PATOFISIOLOGY CHRONIC SUPURATIVE OTITIS MEDIS.**
- 4 EXPLAIN THE CLINICAL MANIFESTATION CHRONIC SUPURATIVE OTITIS MEDIS, INCLUDE THE SIGN AND SIMPTOMS.**
- 5 EXPLAIN THE TREATMENT, COMPLICATION AND PROGNOSIS.**
- 6 PRESENT AND DISCUSS IN CLASS**

**FACULTY OF MEDICINE HASANUDDIN UNIVERSITY**  
**OBJECTIVE STRUCTURED ORAL CASE ANALYSIS**  
**SPECIAL SENSE SYSTEM**  
**OTORHINOLARYNGOLOGY**

**CASE 2**

Male, 18 years came to the clinic with complaints of smelling reduced from six months ago accompanied by nasal congestion, thick mucus that are ingested into the throat, sometimes smells and headache. No complaints of serial sneezing and nasal itching. Previous history of the same disease and a family history of atopy denied.

**Physical examinations:**

General conditions: Good, not anemic. Height: 160 cm, Weight: 60 kg.

Vital signs are within normal limit.

Inspection : The external nose normal

Palpation : No edema and crepitation, tenderness in the left and right cheek  
tenderness on the left and right orbital roof

Otосcopy : Within normal limits

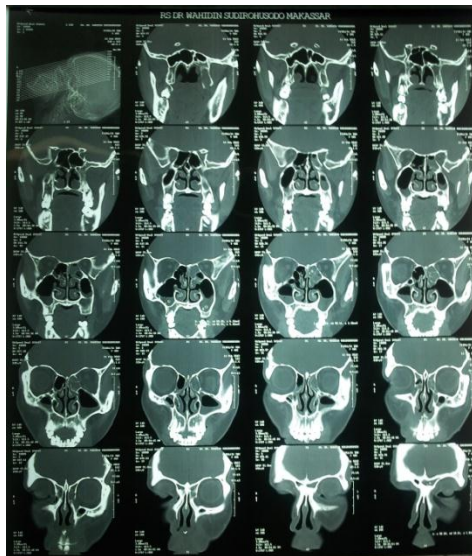
Faringoscopy : Within normal limits

Anterior Rhinoscopy : hyperemic of nasal mucosa, congestion of nasal  
turbinate, there is secret in bilateral of the middle  
nasal meatus and nasal cavity

Laboratory examination : Hb 14 g / dl, leukocytes 12,600 g%

Chest X-Ray : Normal

CT scan :



Diagnosis : Bilateral anterior ethmoidal sinusitis, Left posterior ethmoidal  
sinusitis, Bilateral frontal sinusitis and Bilateral maxillary sinusitis chronic

**BASED ON THE ABOVE CASE, EACH STUDENTS ARE ASSIGNED TO:**

- 1. MAKE A MIND MAP OF CHRONIC SINUSITIS**
- 2. ETIOLOGY OF CHRONIC SINUSITIS**
- 3. SYMPTOMS AND SIGNS OF SMELLING DISTURBANCE**
- 4. SYMPTOMS AND SIGNS OF CHRONIC SINUSITIS.**
- 5. PATHOGENESIS OF CHRONIC SINUSITIS.**
- 6. PATHOPHYSIOLOGY OF SYMPTOMS AND SIGNS OF CHRONIC SINUSITIS.**
- 7. PRINCIPLES OF MANAGEMENT THREATENED CHRONIC SINUSITIS**
- 8. PROGNOSIS OF THREATENED CHRONIC SINUSITIS.**
- 9. CATEGORIES OF CHRONIC SINUSITIS.**
- 10. DIFFERENTIAL DIAGNOSIS OF CHRONIC SINUSITIS**