

MODUL PROBLEM BASED LEARNING SISTEM INDRA KHUSUS



- Modul Gangguan Penglihatan

- Modul Mata Merah

**Diberikan Pada Mahasiswa Semester V
Fakultas Kedokteran Unhas**

**Fakultas Kedokteran
Universitas Hasanuddin
2019**

SHORT OBJECTIVE ORAL CASE ANALYSIS MODULE
OPHTHALMOLOGY
HASANUDDIN UNIVERSITY
2019

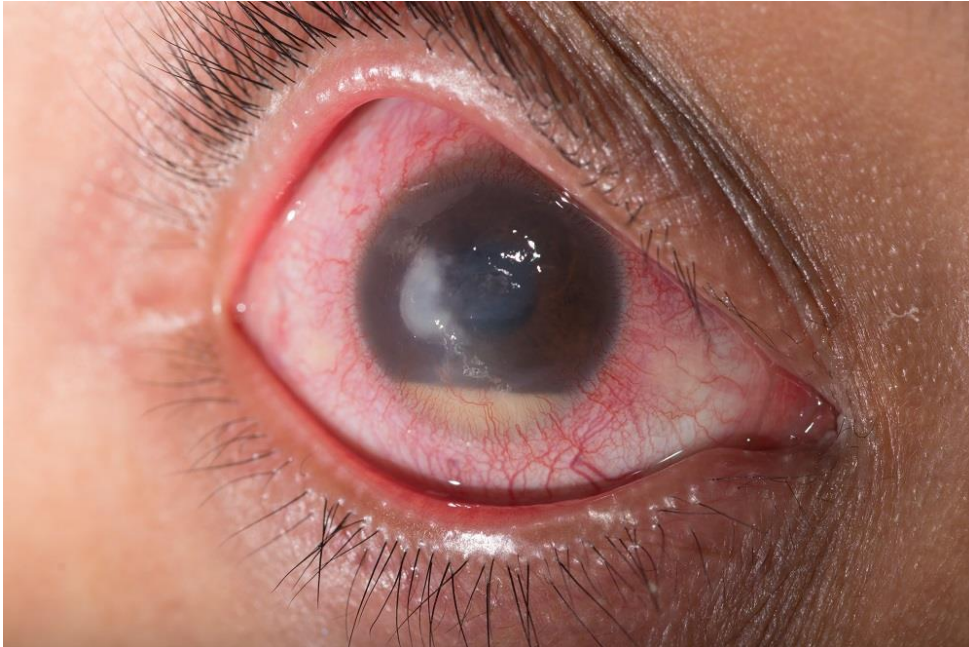Module 1

A 45 year old female patient was diagnosed with Right Eye Corneal Ulcer cum Hipopion based on these findings :

- History : A chief complaint of painful red eye on the right eye, occurred suddenly since 3 days earlier. There was a decreased of vision, profound discharge and tearing. There is a history of trauma of the eye, the right eye was come into contact with sand 4 days prior to visit. There are no history of systemic diseases.
- **Physical findings** : General state : Mild / Good nutrition / Conscious
 - o Vital signs : BP = 110/70; Pulse = 96x/menit; Breathe= 20x/menit; Temp = 37°C
- Ophthalmolgy findings :
 - o Visual Acuity : VOD 1/60, uncorrected; VOS : 6/6
 - o Intraocular Pressure : TOD : Tn TOS : Tn (palpation)
 - o Anterior segment findings

Eye	Right Eye	Left Eye
Palpebra	Edema (+), Blefarospasm	Normal
Cilia	Normal	Normal
Bulbar conjunctiva / Palpebral conjunctiva	Chemosis/ Hyperemic(+) Injeksio ciliaris (+)	Normal/ Hiperemis(-)
Cornea	White lesion (+), Ulcer (+) central	Clear
Anterior chamber	Normal depth, Hypopion (+) ± 1/8 COA	Normal
Iris	Dark brown, crypt(+)	Dark brown, crypt(+)
Pupil	Round, central, light reflex (+)	Round, central, light reflex (+)
Lens	Opaque	Opaque

Posterior segment findings : within normal limits



Picture of the right eye.

EACH STUDENTS ARE ASSIGNED TO

- 1. OUTLINE A MIND MAP OF THIS CASE**
- 2. DESCRIBE THE ETHIOLOGY AND PATHOPHYSIOLOGY OF THIS CASE**
- 3. DESCRIBE CLINICAL MANIFESTATION OF CORNEAL ULCER, INCLUDING ITS SIGNS AND SYMPTOMS.**
- 4. DESCRIBE DIFFERENTIAL DIAGNOSE OF CORNEAL ULCER.**
- 5. DESCRIBE TREATMENTS FOR CORNEAL ULCER AND ITS PROGNOSIS.**
- 6. PRESENT THIS CASE AND DISCUSS IN CLASS**

**SPECIAL SENSE SYSTEM
OPHTHALMOLOGY MODULE
HASANUDDIN UNIVERSITY
2019**

Module 2

A 66 year old man was diagnosed as Hypermature Senile Cataract + secondary glaucoma suspect (ODS), based on these findings :

History: A chief complain of decreased vision on both eyes, aware since \pm 8 months ago and worsened for the past 4 weeks. The patient are not able to do activities due to this complaint. Vision appears to be white, hazy smoke-like and seems to be clearer during night time. Patient complains about recurrent on and off pain on both eyes since 4 days ago, pain is felt on both eyes and spread to the forehead. There was no history of using spectacles for distant vision, and neither of red eyes or trauma of the eye balls. There is a history of hypertension for about 10 years with improper treatment, no history of diabetes mellitus.

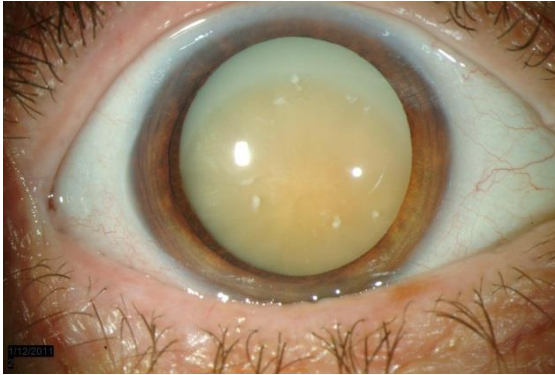
Physical findings: General state : Mild / Good nutrition / Conscious

- **Vital signs :** **BP** = 180/90 mmHg; **Pulse** = 80 x/mnt, **Breathe**= 20x/mnt; **Temp** = 36,7° C
- **Ophthalmology findings :**
 VOD = 1/300; could not be corrected VOS= 1/300; could not be corrected
 IOP : OD : 28 mm Hg OS : 23 mm Hg
- Anterior Segment :

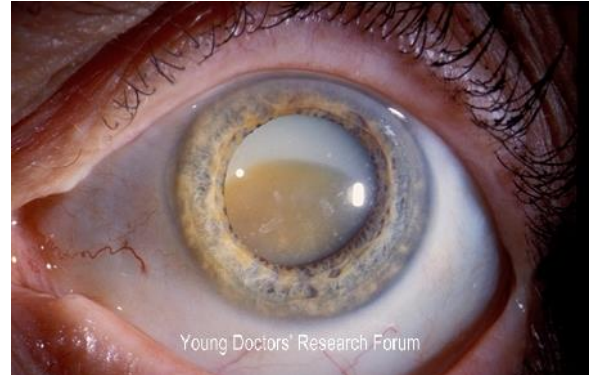Eye	OD	OS
Palpebra	Normal	Normal
Cilia	Normal	Normal
Bulbar conjunctiva / Palpebral conjunctiva	Normal/ Hyperemic(+)	Normal/ Hyperemic(+)
Cornea	Clear	Clear
COA	Normal	Normal
Iris	Dark brown, crypt(+)	Dark brown, crypt(+)
Pupil	Round, central, light reflex (+)	Round, central, light reflex (+)

Lens	Opaque, dense, pseudoiris shadow (+)	Opaque, dense, pseudoiris shadow (+)
------	--------------------------------------	--------------------------------------

OD



OS



Biomicroscopic view of eyes with dilated pupils

- Posterior Segment : Could not evaluated due to opaque cataract
- Lab findings, biometry

Diagnose : ODS Hypermature Senile Cataract + suspect secondary glaucoma

- Treatment plan :
 - o Lowering IOP by medication : Acetazolamide 750 mg tid,
 - o Cataract extraction + IOL implant (Intra Ocular Lens) ODS

EACH STUDENTS ARE ASSIGNED TO :

1. **OUTLINE A MIND MAP OF SENILE CATARACT.**
2. **DESCRIBE RISK FACTORS, PATHOPHYSIOLOGY OF SENILE CATARACT**
3. **DESCRIBE CLINICAL MANIFESTATION OF CATARACT, AND WHAT IS HYPERMATURE CATARACT AND ITS COMPLICATIONS**
4. **DESCRIBE TREATMENTS, POSSIBLE COMPLICATIONS AND ITS PROGNOSIS**
5. **PRESENT AND DISCUSS THIS CASE IN CLASS**

**SHORT OBJECTIVE ORAL CASE ANALYSIS MODULE
OPHTHALMOLOGY
HASANUDDIN UNIVERSITY
2019**

Modul 3

Seorang perempuan, 50 tahun menderita **Proliferative Diabetic Retinopathy**, yang didiagnosis berdasarkan :

History taking:

Keluhan utama berupa penglihatan kedua mata dirasakan kabur 1 tahun ini dan makin memberat sejak 1 bulan terakhir. Keluhan tidak didahului trauma sebelumnya, tidak ada keluhan mata merah, kotoran mata berlebih, silau dan nyeri. Riwayat DM ada, 15 tahun terakhir namun tidak berobat teratur. Tidak ada riwayat penggunaan kaca mata, trauma, penggunaan obat-obatan mata, operasi mata dan penggunaan kacamata sebelumnya.

Pemeriksaan Fisik :

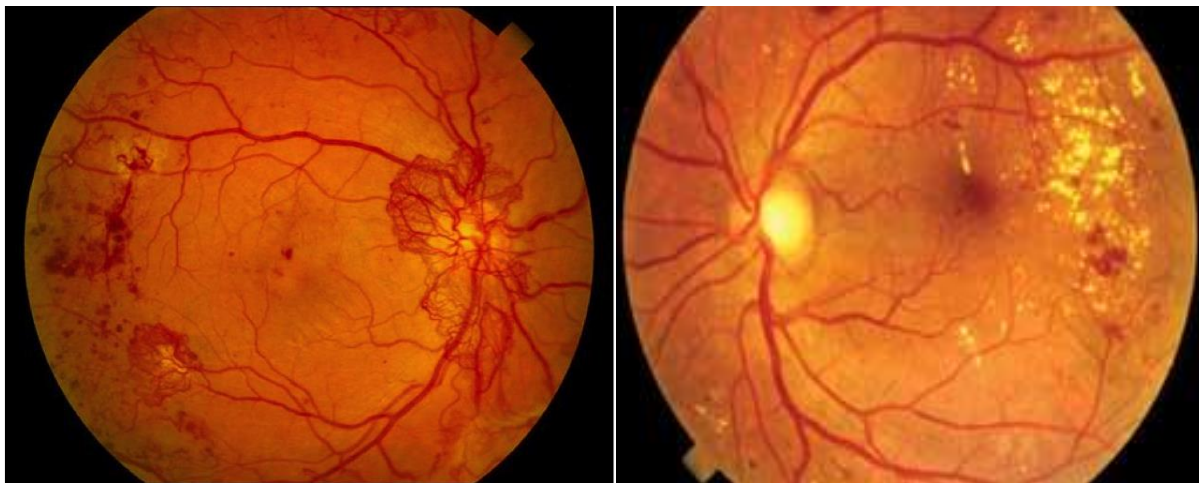
Keadaan Umum : Sakit sedang / Gizi baik/ sadar

- Vital sign : TD = 130/80; Nadi = 80x/mnt; Pernapasan= 20x/mnt; Suhu= 37,1°C

Pemeriksaan Oftalmologi :

- Visual Acuity :
 - OD : 3/60 tidak dapat dikoreksi
 - OS : 2/60 tidak dapat dikoreksi
- Intraocular Pressure : OD : 19 mmHg OS : 19 mmHg
- Segmen Anterior :

Structures of the eye	OD	OS
Palpebra	Normal	Normal
Cilia	Normal	Normal
Konjungtiva bulbi/ Konjungtiva palpebral	Normal/ normal	Normal/ normal
Cornea	Jernih	Jernih
COA	Normal	Normal
Iris	Coklat, kript (+)	Coklat, kript (+)
Pupil	Bulat, reflek pupil (+)	Bulat, reflek pupil (+)
Lens	Agak keruh	Agak Keruh



Posterior segment :

FOD : Refleks fundus (+), Papil nervus II, batas tegas, CDR 0,4, a/v : 2/3, NVD (+), Refleks fovea kesan suram, blot dot (+) Retina perifer : tampak NVE (+) , blot dot hemorrhage (+), Hard eksudates (+), fibrosis (+) di infero medial

FOS : Refleks fundus (+), Papil nervus II, batas tegas, CDR 0,4, a/v : 2/3, Refleks fovea kesan suram, hard eksudat (+), Retina perifer : tampak NVE (+) , blot dot hemorrhage (+), Hard eksudates (+)

Hasil Lab : GDS : 325 mg/dl, HbA1c : 11 %

Diagnosis : ODS. Proliferative Diabetic Retinopathy

STUDENTS ARE ASSIGNED TO :

1. **OUTLINE A MIND MAP FOR THE CASE ABOVE**
2. **EXPLAIN THE ANATOMY OF RETINA**
3. **DESCRIBE THE PATHOPHYSIOLOGY AND CLASSIFICATION OF THE DIABETIC RETINOPATHY**
4. **DESCRIBE SIGNS AND SYMPTOMS OF DR AND EXPLAIN THE MECHANISM OF PATHOLOGICAL SYMPTOMS**
5. **DESCRIBE THE DIFFERENTIAL DIAGNOSE OF THIS CASE**
6. **DESCRIBE ITS TREATMENT, PROGNOSIS, COMPLICATION AND REHABILITATION ON THIS CASE**
7. **PRESENT THIS CASE**